

9, Satya Complex,
 Opposite Sainik petrol pump,
 132 feet ring road,
 (in between shivranjani to shymal)
 Satellite, Ahmedabad - 380015
 Gujarat, India.
 Email: contact@oroscan.com
 Visit us on www.oroscan.com

PATIENT INFORMATION



Name of Patient:					Sex: M / F
Phone No:					Age:
Clinical Note:					
Prints:	Cd		Film		e-mail

REFERRING DOCTOR



Dr.					
Phone No:					
Mail:					
Please attach your visiting card.					

SERVICES



- ORAL RADIOLOGY ORAL PATHOLOGY TOBACCO CESSATION PROGRAM

ORAL RADIOLOGY:

3D DIAGNOSTIC SERVICES



- SECTIONAL CBCT (5 x 5 / 8 x 5) CBCT OF TMJ (RIGHT/LEFT/BOTH)
 CBCT OF MAXILLA (8 x 8) SINUS VIEW
 CBCT OF MANDIBLE (11 x 5) MIDDLE EAR VIEW
 CBCT OF BOTH JAWS (11 x 8) AIR WAY ANALYSIS

Select the Area/Teeth for CBCT



8	7	6	5	4	3	2	1		1	2	3	4	5	6	7	8
8	7	6	5	4	3	2	1		1	2	3	4	5	6	7	8

FOR



- IMPLANT PATHOLOGY ROOT CANAL BONE LOSS IMPACTED THIRD MOLAR

2D DIAGNOSTIC SERVICES



- OPG LATERAL CEPHALOGRAM => TRUE / WITH TRACING PA MANDIBLE / SKULL VIEW
 SUBMENTOVERTEX VIEW TMJ VIEW WATER VIEW HAND WRIST RADIOGRAPH
 REVERSE TOWN VIEW

ADDITIONAL NOTES



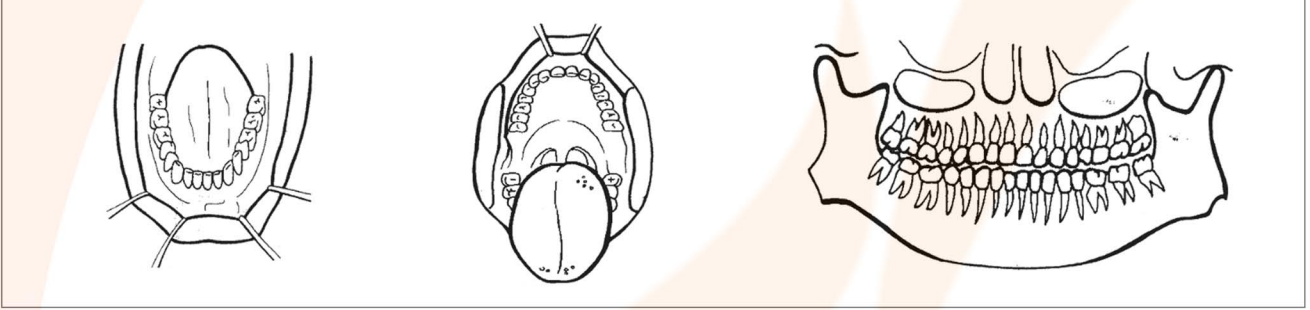
ORAL PATHOLOGY

SPECIMEN TYPE



- EXCISIONAL INCISIONAL SMEAR/ASPIRATION DIRECT IMMUNOFLUORESCENCE

➔ INDICATE SPECIFIC LOCATION OF LESION



BIOPSY LOCATION



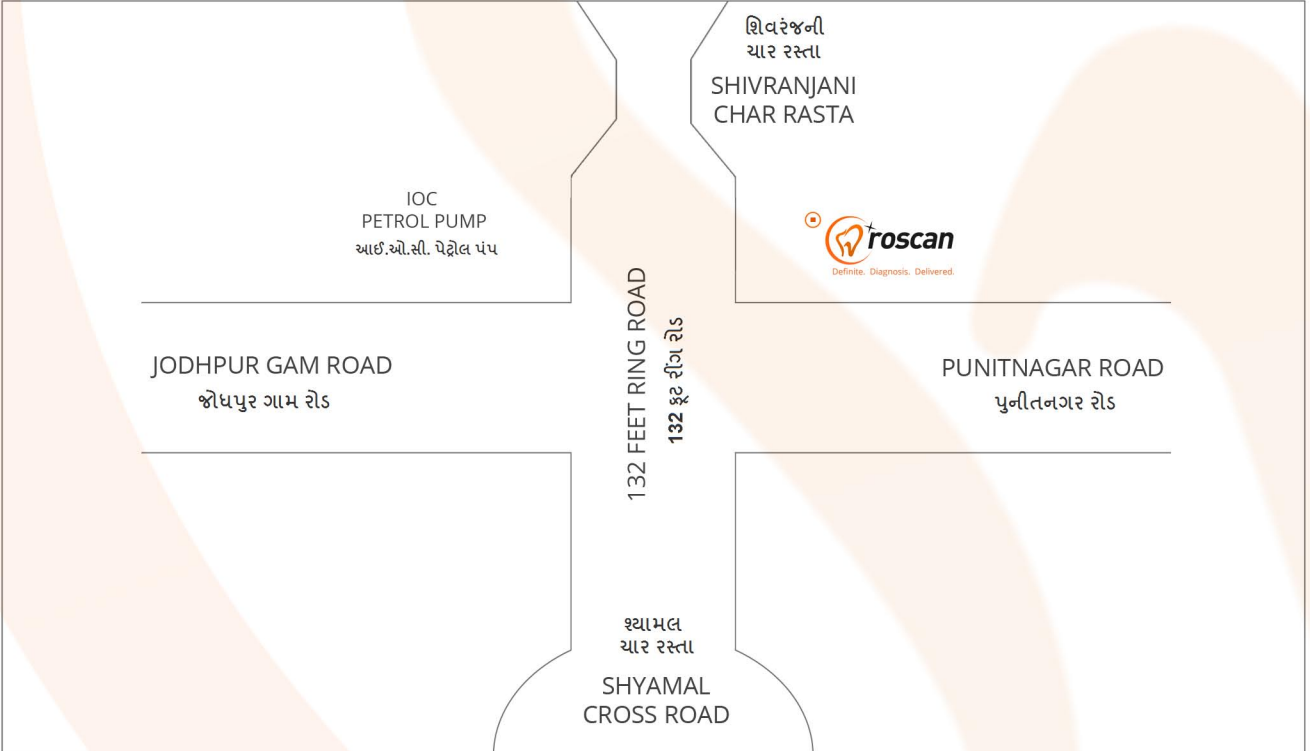
- BUCCAL MUCOSA GINGIVA PALATE (HARD) TEETH TONGUE TONSIL UVULA
 PALATE (SOFT) LEFT RIGHT UPPER LOWER

SIZE: OTHER:

X-RAYS/OTHER PHOTOS ENCLOSED? **: YES NO

(** Include an x-ray with this requisition if the lesion involves bone. **)

Location Map



Contact No:

Dr. Suresh Ludhwani - Oral Radiologist
Mo. (91) 09898864413
Dr. Tapan Modi - Oral Pathologist
Mo. (91) 09427803061
Dr. Chitrag Shah - Tobacco Cessation Expert
Mo. (91) 09898459197

Address:

9, સત્યા કોમ્પ્લેક્સ,
આઈ.ઓ.સી. પેટ્રોલ પંપની સામે,
132 ફૂટ રીંગ રોડ,
(શિવરેજનીથી શ્યામલ ની વચ્ચે)
સેટેલાઈટ, અમદાવાદ - 380015
ગુજરાત, ભારત.